

Transvaginal ultrasonography versus uterine needle biopsy in the diagnosis of diffuse adenomyosis

Paolo Vercellini^{1,3}, Ilenia Cortesi¹, Olga De Giorgi¹, Daniela Merlo², Silvestro G. Carinelli² and Pier Giorgio Crosignani¹

¹Clinica Ostetrica e Ginecologica 'Luigi Mangiagalli', University of Milano, and ²Servizio di Istologia ed Anatomia Patologica, Istituti Clinici di Perfezionamento, Milano, Italy

³To whom correspondence should be addressed at: Clinica Ostetrica e Ginecologica 'Luigi Mangiagalli', Università di Milano, Via Commenda, 12, 20122 Milano, Italy

To assess the reliability of transvaginal ultrasonography and uterine needle biopsy, used singly or in combination, in the diagnosis of diffuse adenomyosis, a prospective study with pathological confirmation of the diagnosis was performed. A total of 102 premenopausal women scheduled for hysterectomy because of menorrhagia and/or pelvic pain underwent preoperative transvaginal ultrasonography. After removal of the uterus, a single full-thickness myometrial biopsy specimen was taken from along the median line in the upper third of the posterior uterine wall, using a 14-gauge Trucut needle. Adenomyosis was diagnosed by the sonographer by the presence of indistinctly demarcated heterogeneous myometrial areas with distorted echotexture, and by the pathologist when the distance between the lower border of the endometrium and the affected myometrial area was more than one-half of a low power field. The prevalence of adenomyosis was 28% (29/102 patients). The sensitivity and specificity of transvaginal ultrasonography were 82.7 and 67.1% respectively, compared with 44.8 and 95.9% for uterine needle biopsy. The positive predictive values of the two tests were 50.0 and 81.2% respectively, and the negative predictive values 90.7 and 81.4%, likelihood ratios of a positive test 2.5 and 10.9, likelihood ratios of a negative test 0.3 and 0.6, and *k* indexes of agreement 0.42 and 0.47. Combining the tests did not improve the overall diagnostic performance. Both transvaginal ultrasonography and uterine needle biopsy demonstrated suboptimal test characteristics.

Key words: adenomyosis/myometrium/needle biopsy/ultrasound/uterus

Introduction

Adenomyosis may be associated with dysmenorrhoea and menorrhagia, constitutes a common indication for hysterectomy, and is often encountered on pathological examination of uteri removed at surgery (Azziz, 1989; Vercellini *et al.*, 1993, 1995, 1996; Brosens *et al.*, 1995a; Parazzini *et al.* 1997).

In the diffuse form of the condition, foci of endometrial glands and stroma are scattered throughout the myometrium. Less frequently, these foci occur in a localized form, the so-called adenomyoma (Zaloudek and Norris, 1994). Until a few years ago, interest in the disease was limited by the impossibility of making a reliable preoperative diagnosis and the absence of alternatives to definitive treatment. Recently, imaging (magnetic resonance imaging, MRI, and pelvic ultrasonography, US) and biopsy (transabdominal or transuterine myometrial biopsy) techniques have been applied to women with suspected adenomyosis in attempts to make diagnoses with the uterus *in situ* (Fedele *et al.*, 1992a,b; McCausland, 1992; Popp *et al.*, 1993; Wood *et al.*, 1993a,b; Ascher *et al.*, 1994; Brosens and Barker, 1995; Brosens *et al.*, 1995b; de Souza *et al.*, 1995; Reinhold *et al.*, 1995; Vercellini *et al.*, 1996). This may be of clinical relevance now that conservative therapeutic options have been developed (Fedele *et al.*, 1993; Wood *et al.*, 1993c). Moreover, identifying adenomyosis before performing endometrial ablation and differentiating adenomyosis from leiomyomas before offering conservative surgery is important for adequate preoperative counselling and for the choice of the correct type of intervention (Fedele *et al.*, 1992b; McCausland and McCausland, 1996; Goldberg *et al.*, 1997). However, information on the best diagnostic modality and on the utility of combining different tests is limited and sometimes contradictory (Ascher *et al.*, 1994; Arnold *et al.*, 1995; Reinhold *et al.*, 1996). Unfortunately, MRI, considered by some authors the most accurate modality for the preoperative diagnosis of adenomyosis (Ascher *et al.*, 1994), is expensive and not always available; hysteroscopic biopsy does not permit histological assessment of the entire uterine wall thickness and may not be acceptable in women wanting children. Therefore, we set out to compare the accuracy of transvaginal US versus myometrial needle biopsy and to evaluate the reliability of the combination of the two tests in the diagnosis of diffuse adenomyosis in a prospective consecutive series of patients undergoing hysterectomy for benign conditions, considering the histological diagnosis based on removed uteri as the reference standard.

Materials and methods

Consecutive premenopausal patients with a uterus measuring less than a 12 week pregnancy undergoing hysterectomy for menorrhagia and/or worsening dysmenorrhoea in an academic department of obstetrics and gynaecology were included in the study. Women with a grossly distorted uterus due to multiple or large leiomyomata or with known endocavitary or endometrial anomalies, or who received steroidal or gonadotrophin-releasing hormone agonist treatment in the preceding 3 months were excluded from the study. Within the

week prior to hysterectomy, all the women underwent US using Ansaldo AU 440 (Ansaldo, Genoa, Italy) or AU 580 synchronous (Hitachi, Tokyo, Japan) equipment and a transvaginal transducer of 6.5 MHz. The sonographer diagnosed adenomyosis by the presence of indistinctly demarcated heterogeneous myometrial areas with distorted echotexture. Myometrial echotexture was defined as distorted by the presence of abnormally decreased or increased echogenicity and/or round anechoic areas (Figure 1). After removal of the uterus, a single full-thickness myometrial biopsy specimen was taken from along the median line in the upper third of the posterior uterine wall using a 14-gauge Trucut needle (Bio-cut, Sterylab S.p.A., Milan, Italy; Figure 2) (Vercellini *et al.*, 1996). Only one expert sonographer interpreted the US examinations and one surgeon performed the uterine biopsies. The uterus was opened by the pathologist at the left margin and fundus and four blocks of uterine wall were examined. All needle biopsy specimens were labelled and stored and then examined on a single occasion at the end of the study. A diagnosis of adenomyosis was made when the distance between the lower border of the endometrium and the affected myometrial area was more than half of a low-power field (~2.5 mm) (Zaloudek and Norris, 1994). The pathologist was blind with respect to the sonographic diagnosis, and, when examining the needle biopsy specimens, unaware of the original histological uterine findings. In cases of doubtful interpretation at US and histological needle biopsy examination, the findings were considered abnormal.

To assess the accuracy of the ultrasonographic and needle-biopsy diagnoses, the sensitivity, specificity, predictive value of an abnormal (PPV) and normal (NPV) test were calculated, considering as the true diagnoses those made at histological examination of the removed uteri (Altman, 1994; Armitage and Berry, 1994; Jaeschke *et al.*, 1994). To evaluate the reliability of combining transvaginal US with myometrial needle biopsy in the diagnosis of adenomyosis, we also calculated the above variables, considering the combination of the tests positive when either of the two was abnormal (to improve sensitivity) and when both were abnormal (to improve specificity) (Altmann, 1994; Armitage and Berry, 1994; Jaeschke *et al.*, 1994). To compare the values of single and combined diagnostic tests in a prevalence-independent manner, we also calculated likelihood ratios for a positive (LR+) and a negative (LR-) test result (Altmann, 1994; Armitage and Berry, 1994; Jaeschke *et al.*, 1994). The *k* statistic was used to evaluate the overall agreement between a test result and the true diagnosis (Landis and Kock, 1977; Fleiss, 1981).

Results

A total of 115 patients was recruited for the study of whom 13 were excluded from analysis for various reasons (performance of transabdominal US alone, two cases; presence of multiple small leiomyomata on the posterior uterine wall making accurate US and needle biopsy difficult, five cases; fragmentation of the needle biopsy specimen, six cases). The mean \pm SD age of the remaining 102 women was 45 ± 6 years. Eighty-six of them were parous and 16 nulliparous. The pathologist diagnosed adenomyosis in the removed uterus in 29 cases, giving an overall prevalence of the condition of 28%. The sonographer diagnosed adenomyosis in 48 subjects, histologically confirmed in 24 cases; that is, US yielded 24 false positive results. The mean \pm SD US uterine volume calculated according to the usual formula for a prolate ellipsoid (length \times width \times depth \times 0.5236) was 129 ± 47 ml in the women with and 116 ± 41 ml in those without adenomyosis. The US finding of anechoic lacunae, which were identified

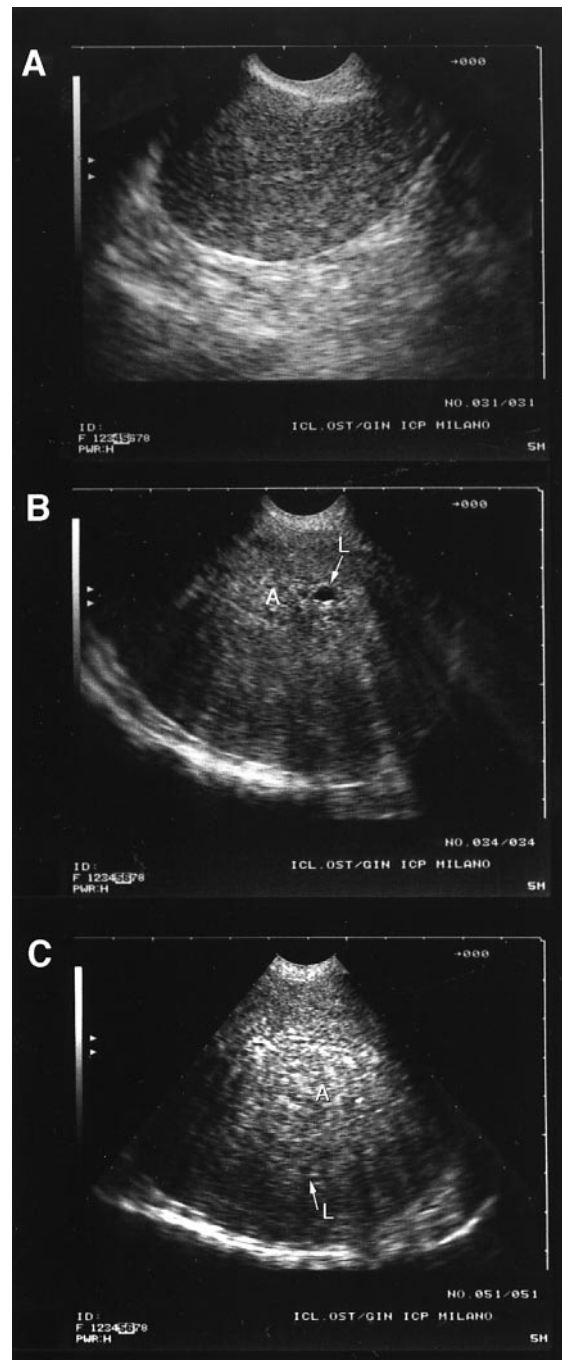


Figure 1. (A) Ultrasonographic pattern of a normal uterus in a longitudinal scan obtained with a transvaginal probe. The anterior and posterior walls show homogeneous myometrium without areas of distorted echotexture. (B) Ultrasonographic pattern of mild diffuse adenomyosis (A) in a longitudinal scan obtained with a transvaginal probe. An indistinctly marginated heterogeneous myometrial area with distorted echotexture and a circumscribed anechoic lacuna (L) are localized within the inner portion of the uterine wall. (C) Ultrasound pattern of severe diffuse adenomyosis (A) in a longitudinal scan obtained with a transvaginal probe. The thickened posterior uterine wall consists of indistinctly marginated heterogeneous myometrial tissue with distorted echotexture. A typical circumscribed anechoic lacuna (L) is observed and asymmetry between the anterior and posterior uterine walls is evident.

but not measured, was associated with the presence of dilated glands within ectopic endometrium. Transvaginal US did not detect adenomyosis in five instances. Myometrial needle biopsy diagnosed adenomyosis in 16 women, which was demonstrated also at histological examination in 13 cases, the other three being false positives. Needle biopsy did not detect adenomyosis in 16 subjects. The combination of two positive tests recognized 10 of the 29 cases of adenomyosis and gave one false positive result. When only one of the two tests was positive the combination yielded only two false negative results, but 26 of the 53 positive diagnoses were not confirmed. The performance of transvaginal US and myometrial needle biopsy, both singly and combined, as a diagnostic test for diffuse uterine adenomyosis is shown in Table I. US had a low PPV (50%) compared both with needle biopsy and with the two tests combined. The LR+ for the combination of two positive tests was 24.6, which indicated that a subject with adenomyosis was almost 25 times more likely to have a positive test than a healthy subject. Furthermore, the optimal LR- (0.1) was obtained with the combination of the two tests but when only one of them was positive. That is, a woman with adenomyosis was one-tenth more likely to have a negative test than a woman without the disease. Overall, the *k* index of agreement between single or combined diagnostic tests and actual histological diagnosis

was only fair, ranging from 0.40 (combination of US and needle biopsy, both positive) to 0.47 (needle biopsy alone).

Discussion

Transvaginal US for the diagnosis of adenomyosis has been evaluated by Fedele *et al.* (1992a) and Brosens *et al.* (1995b) with partly inconsistent results: specificity was 74% in the former and only 50% in the latter study. This is of practical importance for dealing with a chronic condition like adenomyosis which is not life-threatening. In such a situation it is opportune to rely on a test with high specificity in order to avoid undue invasive procedures and unnecessary surgical interventions (Altmann, 1994; Armitage and Berry, 1994). Reinhold *et al.* (1995) have reported a specificity as high as 86% for transvaginal US, and, unlike other authors (Ascher *et al.*, 1994), found that the diagnostic accuracy of US and MRI was similar (Reinhold *et al.*, 1996). Also, myometrial needle biopsy has already undergone evaluation as a single test for adenomyosis with variable test performances depending on the number of biopsies taken and the gauge of the Trucut needle used (Popp *et al.*, 1993; Wood *et al.*, 1993b,c; Brosens and Barker, 1995; Vercellini *et al.*, 1996). In fact, adenomyosis is frequently a patchy disease and the predictive value of a normal needle biopsy specimen may be limited (Zaloudek and Norris, 1994; Vercellini *et al.*, 1996). However, the clinical relevance of needle biopsy, whether US or laparoscopically guided, lies in the possibility of an in-vivo diagnosis; in this circumstance, no more than a single specimen should be taken and considerations on test performance when obtaining multiple biopsies are, in our opinion, of more academic than practical interest. In the present study, the biopsies were done *in vitro* under optimal conditions after hysterectomy; the results of in-vivo biopsies may be less satisfactory because of technical difficulties during the sampling procedure. In all cases we used a 14-gauge Trucut needle, which has a diameter of 2 mm and has been demonstrated to obtain the best specimen for pathological examination (Popp *et al.*, 1993). We performed needle biopsy through the posterior uterine wall because this is the site most frequently involved in diffuse adenomyosis (Zaloudek and Norris, 1994). To our knowledge, this is the first study to compare transvaginal US and needle biopsy in the same series of patients. Three findings at histological examination of needle biopsy specimens were doubtful. In all these instances the positive diagnosis made was false. This was probably due to technical artefacts related to the myometrial

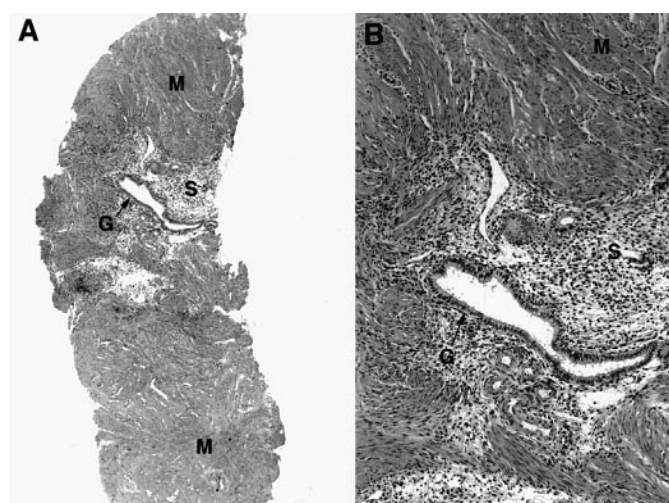


Figure 2. (A) Histological preparation of a uterine needle-biopsy specimen taken from the same patient as Figure 1C. Ectopic endometrial glands (G) and stroma (S) are present in the myometrial muscle wall (M) (haematoxylin and eosin; original magnification $\times 2.5$). (B) Detail of the adenomyotic lesion (haematoxylin and eosin; original magnification $\times 10$).

Table I. Test performance of transvaginal ultrasonography and myometrial needle biopsy in the diagnosis of diffuse adenomyosis

Test characteristic	Ultrasonography alone	Myometrial needle biopsy alone	Ultrasonography and biopsy positive	Ultrasonography or biopsy positive
Sensitivity (%)	82.7	44.8	34.5	93.1
Specificity (%)	67.1	95.9	98.6	64.4
Positive predictive value (%)	50.0	81.2	90.9	50.9
Negative predictive value (%)	90.7	81.4	79.1	95.9
Likelihood ratio for a positive test result	2.5	10.9	24.6	2.6
Likelihood ratio for a negative test result	0.3	0.6	0.7	0.1
<i>k</i> statistic	0.42	0.47	0.40	0.46

sampling technique and/or the preparation of the slides. Although needle biopsy was more specific than US (95.9 versus 67.1%), the sensitivity of the former was so low (44.8%) that it undermined its overall reliability. This is also true when the two tests, both positive, were combined to increase specificity. In fact, this yielded the lowest rate of false positive results (1.4%) among the various test performances, but at the cost of the worst sensitivity (34.5%). The combination of a positive and a negative test produced figures substantially similar to those of US alone and does not seem to be advantageous; in both these instances, a low PPV was observed (about 50%). This last finding is at odds with previous ones reported by Fedele *et al.* (1992a) and Brosens *et al.* (1995b) and may be partly explained by the higher prevalence of disease in those series (respectively 47 and 50%) compared with that in our study population (28%). However, our figure was not unexpected, as it is consistent with the prevalence of adenomyosis observed by us in a large series of patients who underwent hysterectomy for various conditions in our department (Vercellini *et al.*, 1996; Parazzini *et al.*, 1997). The *k* index of agreement with actual histological findings was similar in all diagnostic subgroups and revealed a homogeneously suboptimal performance profile (Landis and Kock, 1977; Fleiss, 1981; Altman, 1994; Armitage and Berry, 1994). Furthermore, inclusion in the analysis of the cases that were not considered for various reasons would probably have influenced the two test performances unfavourably.

In conclusion, in our study transvaginal US and myometrial needle biopsy, whether used singly or in combination, were not highly accurate in the diagnosis of diffuse adenomyosis. According to our experience, myometrial needle biopsy does not seem to add useful information to that obtained at transvaginal US and, in our opinion, should not be implemented in routine practice. Further studies are needed to standardize the correct histological threshold limit for the diagnosis of adenomyosis and to define the potentially more accurate US signs of the disease, as both these variables can greatly influence test performance. Finally, future research should disentangle the contradictory findings on the presumed superiority of MRI compared to US (Ascher *et al.*, 1994; Reinhold *et al.*, 1996) in the preoperative identification of this elusive uterine condition.

References

- Altman, D.G. (1994) Some common problems in medical research. In Altman, D.G. (ed.), *Practical Statistics for Medical Research*. Chapman and Hall, London, pp. 396–439.
- Armitage, P. and Berry, G. (1994) Statistical methods in epidemiology. In Armitage, P. and Berry, G. (eds), *Statistical Methods in Medical Research*. Blackwell Scientific Publications, Oxford, pp. 507–534.
- Arnold, L.L., Ascher, S.M., Schrufer, J.J. *et al.* (1995) The nonsurgical diagnosis of adenomyosis. *Obstet. Gynecol.*, **86**, 461–465.
- Ascher, S.M., Arnold, L.L., Patt, R.H. *et al.* (1994) Adenomyosis: prospective comparison of MR imaging and transvaginal sonography. *Radiology*, **190**, 803–806.
- Azziz, R. (1989) Adenomyosis: current perspectives. *Obstet. Gynecol. Clin. N. Am.*, **16**, 221–235.
- Brosens, J.J. and Barker, F.G. (1995) The role of myometrial needle biopsies in the diagnosis of adenomyosis. *Fertil. Steril.*, **63**, 1347–1349.
- Brosens, J.J., De Souza, N.M. and Barker, F.G. (1995a) Uterine junctional zone: function and disease. *Lancet*, **346**, 558–560.
- Brosens, J.J., De Souza, N.M., Barker, F.G. *et al.* (1995b) Endovaginal ultrasonography in the diagnosis of adenomyosis uteri: identifying the predictive characteristics. *Br. J. Obstet. Gynaecol.*, **102**, 471–474.
- de Souza, N.M., Brosens, J.J., Schwieso, J.E. *et al.* (1995) The potential value of magnetic resonance imaging in infertility. *Clin. Radiol.*, **50**, 75–79.
- Fedele, L., Bianchi, S., Dorta, M. *et al.* (1992a) Transvaginal ultrasonography in the diagnosis of diffuse adenomyosis. *Fertil. Steril.*, **58**, 94–97.
- Fedele, L., Bianchi, S., Dorta, M. *et al.* (1992b) Transvaginal ultrasonography in the differential diagnosis of adenomyoma versus leiomyoma. *Am. J. Obstet. Gynecol.*, **167**, 603–606.
- Fedele, L., Bianchi, S., Zanotti, F. *et al.* (1993) Fertility after conservative surgery for adenomyomas. *Hum. Reprod.*, **8**, 1708–1710.
- Fleiss, J.L. (1981) *Statistical Methods for Rates and Proportions*, 2nd edn. Wiley, New York.
- Goldberg, J.M., Falcone, T. and Attaran, M. (1997) Sonohysterographic evaluation of uterine abnormalities noted on hysterosalpingography. *Hum. Reprod.*, **12**, 2151–2153.
- Jaeschke, R., Guyatt, G.H. and Sackett, D.L. (1994) Users' guides to the medical literature. III. How to use an article about a diagnostic test. B: What are the results and will they help me in caring for my patients? *J. Am. Med. Assoc.*, **271**, 703–707.
- Landis, J.R. and Kock, G.G. (1977) The measurement of observer agreement for categorical data. *Biometrics*, **33**, 159–174.
- McCausland, A.M. (1992) Hysteroscopic myometrial biopsy: its use in diagnosing adenomyosis and its clinical application. *Am. J. Obstet. Gynecol.*, **166**, 1619–1628.
- McCausland, A.M. and McCausland, V.M. (1996) Depth of endometrial penetration in adenomyosis helps determine outcome of rollerball ablation. *Am. J. Obstet. Gynecol.*, **174**, 1786–1794.
- Parazzini, F., Vercellini, P., Panazza, S. *et al.* (1997) Risk factors for adenomyosis. *Hum. Reprod.*, **12**, 1275–1279.
- Popp, L.W., Schwiedessen, J.P. and Gaetje, R. (1993) Myometrial biopsy in the diagnosis of adenomyosis uteri. *Am. J. Obstet. Gynecol.*, **169**, 546–549.
- Reinhold, C., Atri, M., Mehio, A. *et al.* (1995) Diffuse uterine adenomyosis: morphologic criteria and diagnostic accuracy of endovaginal sonography. *Radiology*, **197**, 609–614.
- Reinhold, C., McCarthy, S., Bret, P.M. *et al.* (1996) Diffuse adenomyosis: comparison of endovaginal US and MR imaging with histopathologic correlation. *Radiology*, **199**, 151–158.
- Vercellini, P., Ragni, G., Trespidi, L. *et al.* (1993) Adenomyosis: a déjà vu? *Obstet. Gynecol. Surv.*, **48**, 789–794.
- Vercellini, P., Parazzini, F., Oldani, S. *et al.* (1995) Adenomyosis at hysterectomy: a study on frequency distribution and patient characteristics. *Hum. Reprod.*, **10**, 1160–1162.
- Vercellini, P., Trespidi, L., Panazza, S. *et al.* (1996) Laparoscopic uterine biopsy for diagnosing diffuse adenomyosis. *J. Reprod. Med.*, **41**, 220–224.
- Wood, C., Hurley, V.A. and Leoni, M. (1993a) The value of vaginal ultrasound in the management of menorrhagia. *Aust. N. Z. J. Obstet. Gynaecol.*, **33**, 198–200.
- Wood, C., Hurley, V.A., Fortune, D.W. *et al.* (1993b) Percutaneous ultrasound guided uterine needle biopsy. *Med. J. Aust.*, **158**, 458–460.
- Wood, C., Maher, P. and Hill, D. (1993c) Biopsy diagnosis and conservative surgical treatment of adenomyosis. *Aust. N. Z. J. Obstet. Gynaecol.*, **33**, 319–321.
- Zaloudek, C. and Norris, H.J. (1994) Mesenchymal tumors of the uterus. In Kurmann, R.J. (ed.), *Blaunstein's Pathology of the Female Genital Tract*. Springer Verlag, New York, pp. 487–528.

Received on September 1, 1997; accepted on June 25, 1998